



# Collaborative Regional Benchmarking Group

## Pressure Ulcer Prevention in Critical Care



**Aim:** To provide guidance on Pressure Ulcer Prevention for patients in Critical Care

**Scope:** All adult patients in Critical Care

### Standard Pressure Ulcer Prevention

1	Patients to be assessed for pressure ulcer risk within 6 hours of admission <sup>1</sup> . This should be documented in the patient's records
2	Patient to be on an appropriate pressure relieving surface that is plugged in and working correctly, according to Trust policy <sup>1</sup> .
3	BESTSHOT (see below) areas have been inspected as per risk assessment or at least every 4 hours and documented. The documentation should note skin integrity / condition and any colour changes or discoloration. Particular attention should be focussed around medical devices
4	Medical devices such as endotracheal tube, nasogastric tube, indwelling catheters are repositioned as per risk assessment or at least every 4 hours <sup>1</sup> .
5	Documented evidence that the patient has been repositioned as per risk assessment or at least 4 hourly unless clinically contraindicated <sup>1</sup> . (NB. Position changes or clinical contraindications to repositioning should be clearly documented)
6	The patient's skin must be kept clean and dry <sup>1,2</sup> . Where this is not possible, are appropriate measures being taken to minimise /prevent moisture build up e.g. barrier creams /absorbent dressings.
7	A daily (MDT) review of nutrition and hydration status (e.g. ward round), including dietetic referral where appropriate <sup>3</sup> .

<b>B</b>	<b>BUTTOCKS</b>	<b>If pressure damage/MASD is present</b> <ul style="list-style-type: none"> <li>Discuss with your nurse in charge and/or Tissue Viability Link nurses</li> <li>Increase repositioning schedule</li> <li>Commence wound care plan</li> <li>Consider using additional pressure relieving equipment e.g. mattresses, cushions, boots.</li> <li>Follow local guidance on reporting pressure damage/MASD (DATIX, RCA, Stop the line)</li> <li>Consider medical photography</li> </ul>	<b>Consider referrals to other members of the MDT</b> <ul style="list-style-type: none"> <li>Tissue Viability for advice and treatment plans</li> <li>Dietician for high calorie/protein diet that will be required for wound healing.</li> <li>Consider commencing oral supplements.</li> <li>Physiotherapy to assist patients and staff with repositioning/mobility.</li> <li>Diabetic and vascular teams for advice</li> </ul>
<b>E</b>	<b>ELBOWS / EARS</b>		
<b>S</b>	<b>SACRUM</b>		
<b>T</b>	<b>TROCHANTERS (Hips)</b>		
<b>S</b>	<b>SPINE / SHOULDERS</b>		
<b>H</b>	<b>HEELS</b>		
<b>O</b>	<b>OCCIPITAL AREA</b>		
<b>T</b>	<b>TOES</b>		

#### Pressure V's Moisture Associated Skin Damage (MASD)

- Pressure damage will normally be over a bony prominence or caused by a device
- Pressure damage will have more defined edges and is likely to be a more regular shape
- MASD will be diffuse, with irregular edges shaped across both buttocks
- Elongated shaped damage to the natal cleft are most likely to be moisture
- Pressure damage will be non blanching
- MASD can be caused by incontinence, oedema, leaking wounds/drains/stoma sites.
- MASD will increase the susceptibility to pressure damage

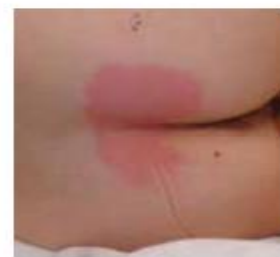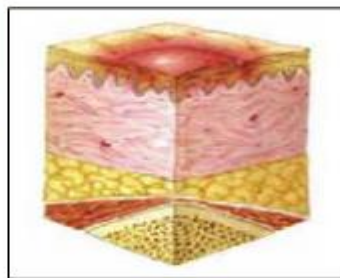
**Refer to local guidelines for more information**

2024 V3

## Category/Stage I: Nonblanchable Erythema

Intact skin with non-blanchable redness of a localized area usually over a bony prominence. Darkly pigmented skin may not have visible blanching; its color may differ from the surrounding area.

The area may be painful, firm, soft, warmer or cooler as compared to adjacent tissue. Category/Stage I may be difficult to detect in individuals with dark skin tones. May indicate "at risk" individuals (a heralding sign of risk).

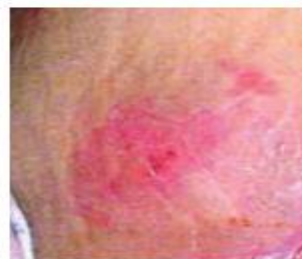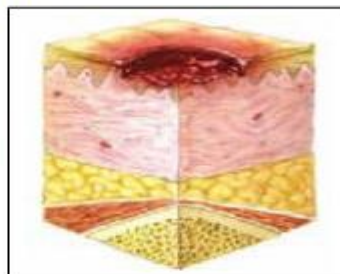


## Category/Stage II: Partial Thickness Skin Loss

Partial thickness loss of dermis presenting as a shallow open ulcer with a red pink wound bed, without slough. May also present as an intact or open/ruptured serum-filled blister.

Presents as a shiny or dry shallow ulcer without slough or bruising.\* This Category/Stage should not be used to describe skin tears, tape burns, perineal dermatitis, maceration or excoriation.

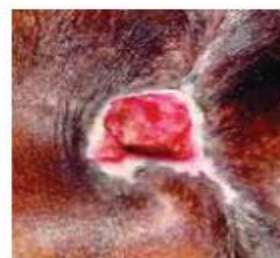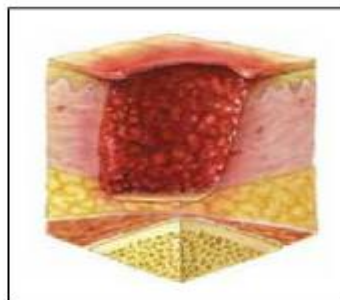
*\*Bruising indicates suspected deep tissue injury.*



## Category/Stage III: Full Thickness Skin Loss

Full thickness tissue loss. Subcutaneous fat may be visible but bone, tendon or muscle are not exposed. Slough may be present but does not obscure the depth of tissue loss. May include undermining and tunneling.

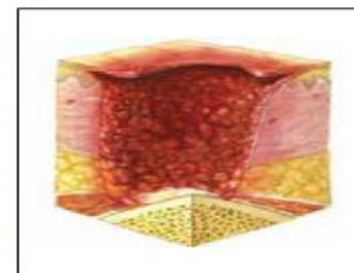
The depth of a Category/Stage III pressure ulcer varies by anatomical location. The bridge of the nose, ear, occiput and malleolus do not have subcutaneous tissue and Category/Stage III ulcers can be shallow. In contrast, areas of significant adiposity can develop extremely deep Category/Stage III pressure ulcers. Bone/tendon is not visible or directly palpable.



## Category/Stage IV: Full Thickness Tissue Loss

Full thickness tissue loss with exposed bone, tendon or muscle. Slough or eschar may be present on some parts of the wound bed. Often include undermining and tunneling.

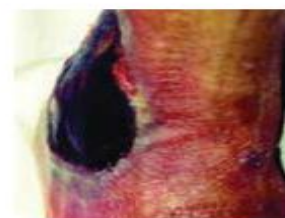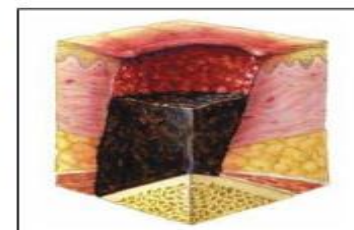
The depth of a Category/Stage IV pressure ulcer varies by anatomical location. The bridge of the nose, ear, occiput and malleolus do not have subcutaneous tissue and these ulcers can be shallow. Category/Stage IV ulcers can extend into muscle and/or supporting structures (e.g., fascia, tendon or joint capsule) making osteomyelitis possible. Exposed bone/tendon is visible or directly palpable.



## Unstageable: Depth Unknown

Full thickness tissue loss in which the base of the ulcer is covered by slough (yellow, tan, gray, green or brown) and/or eschar (tan, brown or black) in the wound bed.

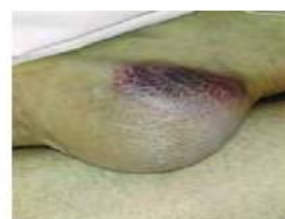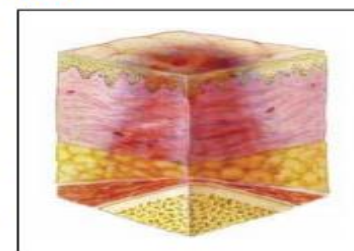
Until enough slough and/or eschar is removed to expose the base of the wound, the true depth, and therefore Category/Stage, cannot be determined. Stable (dry, adherent, intact without erythema or fluctuance) eschar on the heels serves as 'the body's natural (biological) cover' and should not be removed.



## Suspected Deep Tissue Injury: Depth Unknown

Purple or maroon localized area of discolored intact skin or blood-filled blister due to damage of underlying soft tissue from pressure and/or shear. The area may be preceded by tissue that is painful, firm, mushy, boggy, warmer or cooler as compared to adjacent tissue.

Deep tissue injury may be difficult to detect in individuals with dark skin tones. Evolution may include a thin blister over a dark wound bed. The wound may further evolve and become covered by thin eschar. Evolution may be rapid exposing additional layers of tissue even with optimal treatment.



	<b>References</b>
1	National Institute for Health and Care Excellence (2014) Pressure Ulcers: Prevention and Management. Clinical guidance No. 179. NICE, London
2	Voegeli D (2019) Prevention and management of moisture-associated skin damage. Nursing Standard. 34, 2, 77-82. doi: 10.7748/ns.2019.e11314
3	Posthauer ME, Banks M, Dorner B, Schols JM. The role of nutrition for pressure ulcer management: National pressure ulcer advisory panel, European pressure ulcer advisory panel, and pan pacific pressure injury alliance white paper. Adv Skin Wound Care. 2015;28:175–88